

MADE FOR NEW YORK.



Dr. Laith M. Jazrawi

Chief, Division of Sports Medicine
Associate Professor Department of Orthopaedic Surgery

Rehabilitation Guidelines for Biceps Tenodesis

The shoulder has two primary joints. One part of the shoulder blade, called the glenoid fossa forms a flat, shallow surface. This is coupled with the humerus (shaped like a golf ball) to make up the joint. The glenoid labrum is a "ring" of cartilage that turns the flat surface of the glenoid into a slightly deeper socket, which is similar to resting a golf ball on a golf tee instead of a table top, providing more shoulder stability. Another part of the scapula, called the acromion, articulates with the clavicle (collar bone) to make the acromioclavicular (AC) joint.

The rotator cuff is a group of four muscles: the supraspinatus, infraspinatus, teres minor, and subscapularis. The rotator cuff tendons attach around the humeral head (ball) and connect the humerus to the scapula.

The long head of the biceps originates from the top of the glenoid fossa and labrum (top of the golf tee). It then runs through a groove in the humerus (upper arm bone) to join the short head of the biceps and inserts on a bone in the forearm¹ (See Figure 1). Because of its position, the long head of the biceps is also considered to be a secondary stabilizer of the shoulder joint.

The long head of the biceps is at risk of injury and degenerative changes due to its proximity to the rotator cuff and the acromion. Since the long head of the biceps can act as a secondary stabilizer of the shoulder, it is also subject to injury during high speed overhead movements; repetitive overhead movements; or forceful shoulder activities when the elbow is straight. Specific injuries may include inflammation and irritation of the bicep tendon itself; a problem with the bicep tendon in conjunction with one of the rotator cuff tendons; or detachment of part of the tendon from the attachment point (SLAP tear).¹ Bicep tendon degeneration and/or tearing can cause significant shoulder discomfort and dysfunction (See Figure 2).

A biceps tenodesis is a surgical procedure which may be performed for treatment of severe symptoms involving the biceps tendon, including inflammation or partial tears. It may be performed in isolation or as part of a larger shoulder surgery, including surgery involving the rotator cuff. During the biceps tenodesis, the normal attachment of the biceps tendon on the shoulder socket (glenoid fossa) is cut and reattachment of the tendon is made on the humerus (upper arm bone). This takes the pressure off the biceps attachment and places the attachment below the actual shoulder joint.² The goal is to eliminate the shoulder pain coming from the bicep tendon. Different techniques are used to perform a biceps tenodesis. The surgical techniques can be broken down in to two categories: soft tissue techniques and hardware fixation techniques. Both techniques are effective and chosen based on surgeon preference and patient indications.

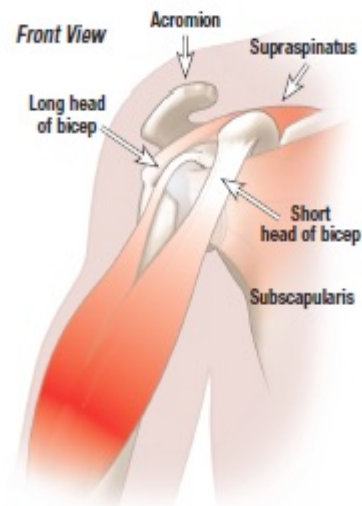


Figure 1 Shoulder anatomy

Rehabilitation Protocol After Biceps Tenodesis

The primary soft tissue technique is the “open key hole procedure”. An open keyhole technique relocates the tendon within the groove in the humerus bone after cutting it from its original location in the shoulder.¹ The procedure involves the proximal end (the portion closest to the it from its original location in the shoulder.) of the biceps tendon being rolled into a ball and then sutured together as a mass. A keyhole is made in the groove of the humerus, the tendon mass is then inserted into the keyhole and pulled downward so that the tendon mass is locked in place.³

The Pitt technique uses two needles to pierce the bicep tendon in opposite directions. Sutures are then threaded through the needles to make a suture. This procedure is repeated with the needle placement reversed to create a locking pattern of the sutures. A knot is used to secure the sutures to the transverse ligament in the shoulder instead of to the bone.⁴

The hardware fixation techniques include screw fixation or endobutton fixation. In the screw fixation the tendon is detached and then place in a hole made at the top of the bicipital groove. Then an interference screw is placed over the tendon, in to the bone, to hold it in place. In the endobutton technique the released tendon is secured to a button, the button is then secured behind the bone by sliding it in to a smaller hole at the top of the bicipital groove. Imagine a drywall type anchor where the pressure is applied from the inside out.

Appropriate rehabilitation is vital to optimizing your outcome after surgery. The rehabilitation guidelines are tailored to the type of procedure performed, therefore below you will find rehabilitation guidelines for soft tissue fixation techniques and rehabilitation guidelines for hardware fixation techniques. The rehabilitation guidelines are presented in a criterion based progression. General time frames are given for reference to the average, but individual patients will progress at different rates depending on their age, associated injuries, pre-injury health status, rehabilitation compliance and injury severity. Specific time frames, restrictions and precautions may also be given to protect healing tissues and the surgical repair/reconstruction.

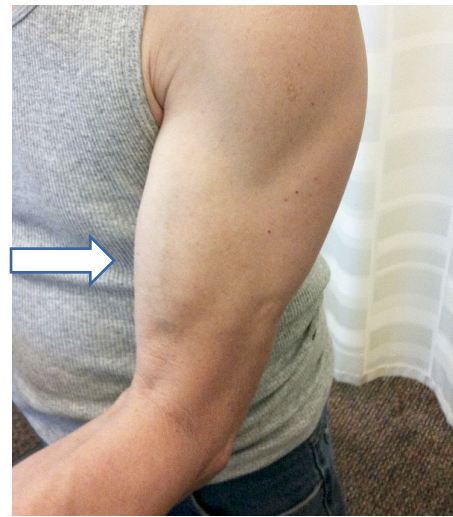

Figure 2a Normal long head of bicep. The muscle has a smooth arc from the shoulder to the elbow

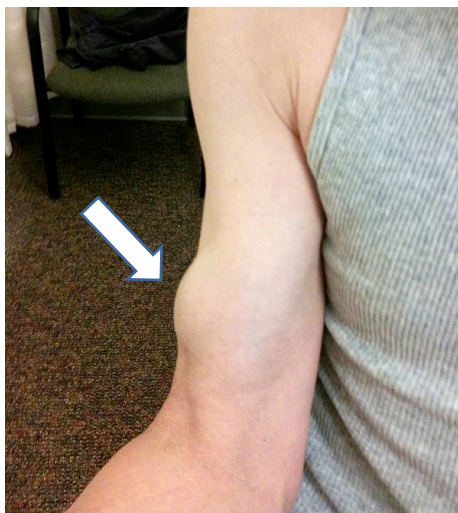
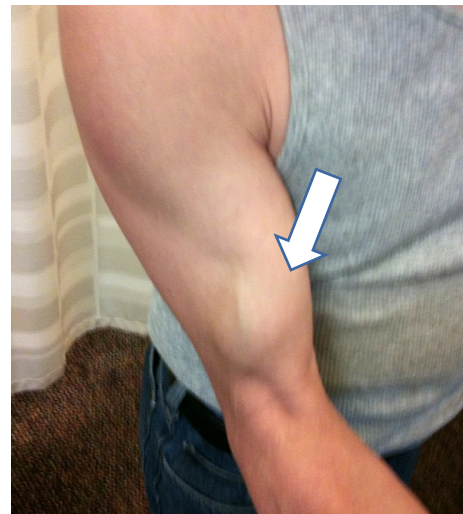
Figure 2b and Figure 2c Torn long head of bicep. The muscle has retracted toward the elbow



Rehabilitation Protocol After Biceps Tenodesis

Phase I (Surgery to 4 weeks after surgery)

Goal	<ul style="list-style-type: none"> ○ Sling immobilization to be worn at all times for showering and rehab under guidance of PT ○ Goals: full passive flexion/extension at elbow and full shoulder AROM
Range of Motion	<ul style="list-style-type: none"> ○ PROM→AAROM→AROM of elbow as tolerated without resistance (allows biceps tendon to heal into new insertion on the humerus without being stressed), AROM of shoulder (no restriction) ○ Encourage pronation/supination without resistance
Therapeutic Exercises	<ul style="list-style-type: none"> ○ Grip strengthening ○ Heat/Ice before and after PT sessions

Phase II (4 to 12 weeks following surgery)

Goals	<ul style="list-style-type: none"> ○ Discontinue sling immobilization
Range of Motion Exercises	<ul style="list-style-type: none"> ○ Being AROM of elbow with passive stretching at end ranges to maintain/increase elbow/biceps flexibility
Therapeutic Exercises	<ul style="list-style-type: none"> ○ Begin light isometrics with arm at side for rotator cuff and deltoid – can advance to bands as tolerated ○ Begin light resistive biceps strengthening at 8 weeks

Phase III (3 to 6 month following surgery)

Range of Motion Exercises	<ul style="list-style-type: none"> ○ Progress to full AROM of elbow without discomfort
Therapeutic Exercises	<ul style="list-style-type: none"> ○ Continue and progress with Phase II exercises ○ Begin UE ergometer ○ Begin sport-specific rehabilitation ○ Return to throwing at 3 months ○ Throwing from a mound at 4.5 months ○ Return to sports at 6 months if approved

Rehabilitation Protocol After Biceps Tenodesis

References

1. Krupp RJ, Kevern MA, Gaines MD, Kotara S, Singleton SB. Long Head of the Biceps Tendon Pain: Differential Diagnosis and Treatment. *Jour Ortho & Sports PT*. Feb 2009; 39(2): 55-70.
2. Romeo AA, Mazzocca AD, Tauro JC. Arthroscopic Biceps Tenodesis. *Arthroscopy*. Feb 2004; 20(2): 206-213.
3. Ozalay M, et al. Mechanical Strength of Four Different Biceps Tenodesis Techniques. *Arthroscopy: Jour Arthro & Related Surg*. Aug 2005; 21(8): 992-998.
4. Lopez-Vidriero E, Costic RS, Fu FH, Rodosky MW. Biomechanical Evaluation of 2 Arthroscopic Biceps Tenodesis: Double-Anchor Versus Percutaneous Intra-Articular Transtendon (PITT) Techniques. *Am Jour Sports Med*. 2010; 38(1): 146-152.
5. Slenker NR, Lawson K, Ciccotti MG, Dodson CC, Cohen SB. Biceps tenotomy versus tenodesis: clinical outcomes. *Arthroscopy*. 2012 Apr;28(4):576-82. doi: 10.1016/j.arthro.2011.10.017. Epub 2012 Jan 28.
6. Burns JP, Bahk M, Snyder SJ. Superior labral tears: repair versus biceps tenodesis. *J Shoulder Elbow Surg*. 2011 Mar; 20(2 Suppl):S2-8. doi: 10.1016/j.jse.2010.11.013.