

MADE FOR NEW YORK.



Dr. Laith M. Jazrawi

Chief, Division of Sports Medicine
Associate Professor Department of Orthopaedic Surgery

Rehabilitation Guidelines for Knee Arthroscopy

Arthroscopy is a common surgical procedure in which a joint is viewed using a small camera. This technique allows the surgeon to have a clear view of the inside of the knee, which helps diagnose and treat knee problems. Recent advances in technology have led to high definition monitors and high resolution cameras. These and other improvements have made arthroscopy a very effective tool for treating knee problems. According to the American Orthopaedic Society for Sports Medicine, more than 4 million knee arthroscopies are performed worldwide each year.⁵ Knee arthroscopy can be used to treat meniscal and articular cartilage tears, fat pad impingement and chronic plica irritation.

There are two types of cartilage in the knee, articular cartilage and meniscus cartilage. Articular cartilage is made up of collagen, proteoglycans and water, which line the end of the bones that meet to form a joint. The primary function of the articular cartilage is to provide a smooth gliding surface for joint motion. Rubbing articular cartilage on articular cartilage is approximately 5 times more smooth (i.e. less friction), than rubbing ice on ice.³ A wide range of injuries can occur to the articular cartilage during sports injuries, trauma and degenerative processes. Smaller, partial thickness tears of the articular cartilage can cause pain, swelling, or catching in the knee. These types of tears can be treated with arthroscopy by removing the torn or frayed articular cartilage with a shaver. The goal of this is to remove the damaged articular cartilage while preserving the remaining intact articular cartilage.

The meniscus cartilage in the knee includes a medial (inside part of the knee) meniscus and a lateral (outside part of the knee) meniscus (Figures 1 and 2). Together they are referred to as menisci. The menisci are wedge shaped and are thinner toward the center of the knee and thicker toward the periphery of the knee joint (Figures 1 and 3). This shape is very important to its function since the primary function of the menisci is to improve load transmission. A relatively round femur sitting on a relatively flat tibia forms the knee joint. Without the menisci the area of contact force between these two bones would be relatively small, increasing the contact stress by 235-335% (Figure 4). The menisci also provide some shock absorption, lubrication and joint stability.

There are two categories of meniscal tears, acute traumatic tears and degenerative tears. Degenerative tears occur most commonly in middle-aged people as a result of repetitive stresses to the menisci over time, which severely weaken the tissue and cause a nonacute, degenerative tear. This process of tissue degeneration makes it very unlikely that a surgical repair will heal or that the surrounding meniscus will be strong enough to hold the sutures use to repair it.

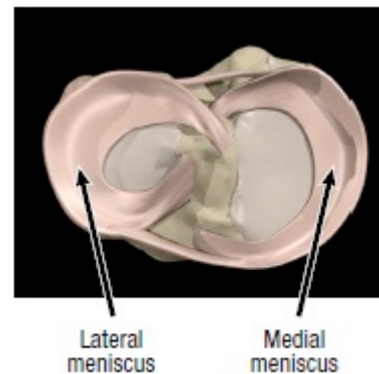


Figure 1 Lateral and medial meniscus of the left knee (shown here from above the knee, without the femur)

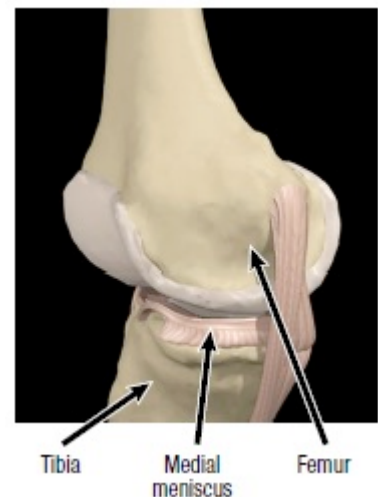


Figure 2 Medial (inside) view of the knee

Rehabilitation Protocol After Knee Arthroscopy

One report showed that less than 10% of meniscal tears occurring in patients more than forty years of age were repairable. Symptoms of a degenerative meniscus may include swelling, pain along the joint line, catching, and locking. If a degenerative tear is symptomatic it is usually surgically removed. This is called a partial meniscectomy, which is termed partial because the surgeons only remove the segment of meniscus containing the tear as opposed to removing the entire meniscus.

Acute traumatic tears occur most frequently in the athletic population as a result of a twisting injury to the knee when the foot is planted. Symptoms of an acute meniscus tear include swelling, pain along the joint line, catching, locking and a specific injury. Often times these tears can be diagnosed by the history of the problem and a good physical examination. Sometimes an MRI will be used to assist in making the diagnosis. The arrow in Figure 3 shows a normal meniscus on an MRI, but the arrows in Figure 5 show a torn meniscus.

If an athlete suffers a meniscal tear the three options for treatment include: non-operative rehabilitation; surgery to trim out the area of torn meniscus; or surgery to repair (stitch together) the torn meniscus. The treatment chosen will depend on the location of the tear; the size of the tear; the sport to which the athlete is returning; ligamentous stability of the knee; and any associated injury.² The location of the tear is important because the outer portion of the meniscus has a good blood supply whereas the inner portion has a very poor blood supply. Blood vessels (the perimeniscular capillary plexus) enter the peripheral one third of the meniscus,¹ this blood supply is necessary for a tear or surgical repair to heal (Figure 6). Without an adequate blood supply, usually the area of torn meniscus has to be removed.

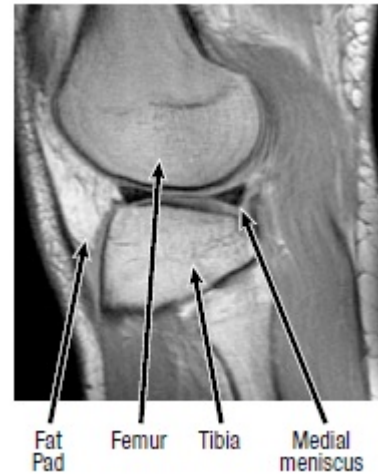
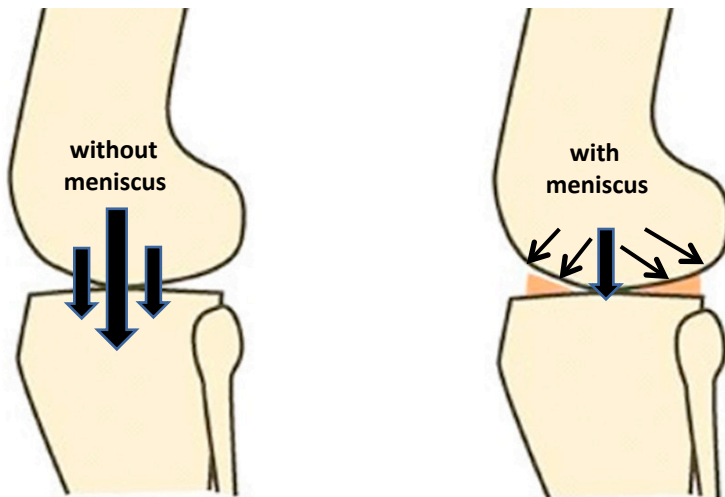


Figure 3 Normal MRI (sagittal view) of the knee, lateral side (outside)

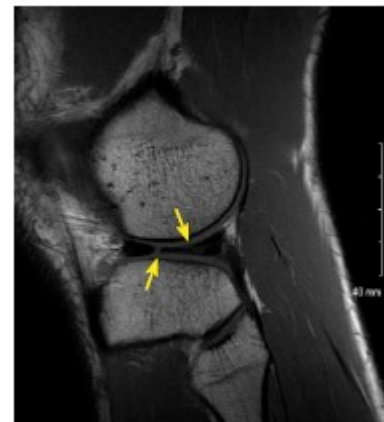

Figure 5 MRI (sagittal view) of a lateral meniscus tear (yellow arrows)

Figure 4 Schematic representation of the meniscal effect on contact pressure in the knee. Contact area is increased by 50% with addition of menisci. This reduces contact pressures.

Rehabilitation Protocol After Knee Arthroscopy

Other structures in the knee that can cause pain and limit function when injured or chronically inflamed are the fat pad (Figure 3) and the plica. These problems can arise from a variety of causes, but if they do not improve with non-surgical measures it may be necessary to use knee arthroscopy to remove the tissue. Secondary problems may also arise from injury, such as scar tissue or cysts, which need to be removed. After knee arthroscopy, rehabilitation with a physical therapist or athletic trainer is usually required to optimize the outcome. Rehabilitation will focus on restoring range of motion, developing strength and movement control, and guiding the athlete's return to sport. The rehabilitation guidelines are presented in a criterion based progression. Specific time frames, restrictions and precautions are given to protect healing tissues and the surgical repair/reconstruction. General time frames are also given for reference to the average, but individual patients will progress at different rates depending on their age, associated injuries, pre-injury health status, rehabilitation compliance and injury severity. The size and location of the meniscal tear also may affect the rate of post-operative progression.

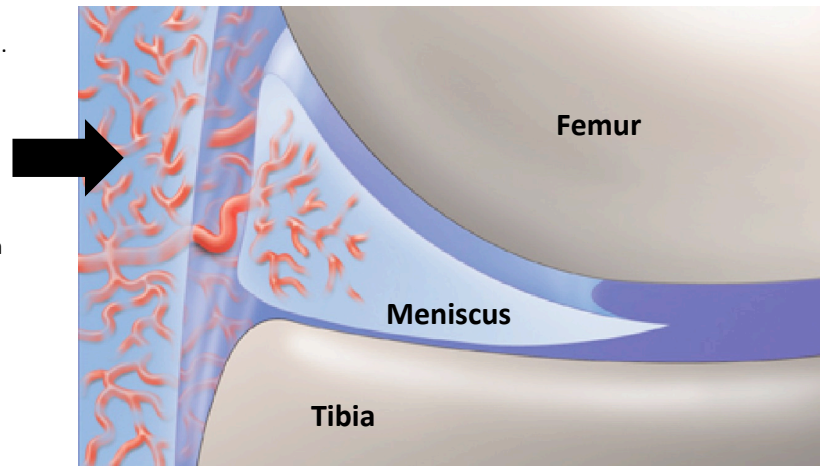


Figure 6 Perimeniscal capillary plexus (thick arrow) providing blood supply to the outer third of the meniscus

References

1. Arnoczky SP and Warren RF. Microvasculature of the human meniscus. *Am J Sport Med*, 1982
2. Fowler PJ and Pompan D. Rehabilitation after mensical repair. *Tech in Ortho*, 8(2): 137-139, 1993.
3. Ulrich GS and Aronczyk SP. The basic science of meniscus repair. *Tech in Ortho*, 8(2): 56-62, 1993.
4. Zacharias J. Mensical Injuries: Anatomy, Diagnosis and Treatment. *UW Sports Medicine conference*. September 8, 1999.
5. American Academy of Orthopedic Surgeons: orthoinfo.aaos.org