

MADE FOR NEW YORK.



Dr. Laith M. Jazrawi

Chief, Division of Sports Medicine
Associate Professor Department of Orthopaedic Surgery

Rehabilitation Protocol for Lateral Ankle Reconstruction

The ankle is a very complex joint. There are actually three joints that make up the ankle complex: the tibiotalar joint, the subtalar joint and the distal tibiofibular joint. Stability of a joint is maintained by connective tissue structures and the dynamic support of the surrounding muscles. The primary stabilizing connective tissues are ligaments. A ligament connects bone to bone to limit excessive movement. The outside (lateral) ankle complex is stabilized at each of the three joints by three major ligaments. The tibiotalar joint is stabilized by the anterior talofibular (ATFL) ligament. The subtalar joint is stabilized by the calcaneofibular (CF) ligament and the tibiofibular joint is stabilized by the anterior and posterior tibiofibular (ATFL and PTFL) ligaments (Figure 1).

The muscles of the lower leg, ankle and foot also help to stabilize the ankle joint dynamically. When the ankle complex starts to move excessively in one direction, reactive corrective ring of the opposite muscle groups can help stabilize the joint. The muscles that are primarily responsible for preventing lateral ankle sprains are the peroneus longus and brevis (Figure 2). The ability for these muscles to react quickly is not only related to their strength but more importantly by proprioception, which is the body's ability to sense the position of the joint and subsequently correct it as necessary by sending nerve impulses to the appropriate muscles. Proprioception can be enhanced or trained with the use of balance exercises so these are commonly used in ankle sprain prevention and rehabilitation programs.

Lateral ankle sprains are very common, especially in sports such as basketball and volleyball. Generally athletes recover well from this type of injury with physical therapy and rehabilitation. However, up to 20% of lateral ankle sprains can lead to chronic pain and instability. This instability may occur via repetitive ankle sprains or even progress to the ankle giving way with routine daily activities. Aggressive rehabilitation, bracing, taping and orthotics are all non-surgical options that may be appropriate to prevent instability.

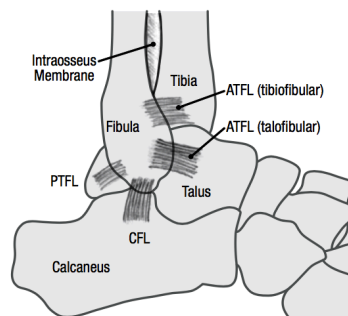


Figure 1

Rehabilitation Protocol for Lateral Ankle Reconstruction

If these measures fail to control the instability it may be necessary to restore the anatomy of the lateral ankle with surgical reconstruction. The preferred surgical method is to perform an anatomic repair of the anterior talofibular and calcaneofibular ligaments via a technique called the Brostrom repair, which involves shortening the attenuated ligaments and a direct repair with suture fixation. When the anatomical repair is reinforced with the advancement of the inferior extensor retinaculum, it is called the modified Brostrom repair. When the repair is further augmented with a slip of the peroneus brevis tendon through a drill hole in the fibula it is referred to as a modified Brostrom- Evans technique. The peroneus brevis tendon then acts as a check to inversion stresses and provides reinforcement to the anatomical repair without limiting long-term inversion/eversion motion or strength. For revision surgeries or in the case of excessive instability, an allograft (cadaver tissue, usually a tendon) may be needed to reconstruct both the anterior talofibular and calcaneofibular ligaments.

After surgery, rehabilitation with a physical therapist or athletic trainer is needed to restore range of motion, strength, proprioception, movement control and guide the athlete's return to sport. The rehabilitation guidelines are presented in a criterion based progression. Specific time frames, restrictions and precautions are given to protect healing tissues and the surgical repair/reconstruction. General time frames are also given for reference to the average individual, but individual patients will progress at different rates depending on their age, associated injuries, pre-injury health status, rehabilitation compliance and injury severity. The technique used for reconstruction may alter the rehabilitation as well.

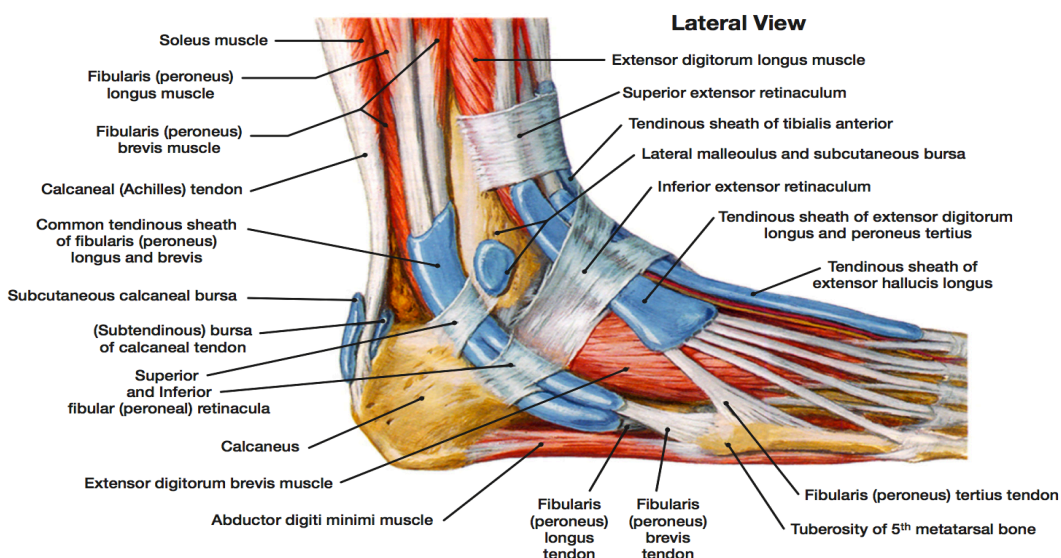


Figure 2