

Dr. Laith M. Jazrawi

Chief, Division of Sports Medicine
Associate Professor Department of Orthopaedic Surgery

Rehabilitation Protocol After Anterior Shoulder Reconstruction with Open Bankart Repair

The anatomic configuration of the shoulder joint (glenohumeral joint) is often compared to a golf ball on a tee (Figure 1). This analogy is used because the articular surface of the round humeral head (upper most part of the arm) is approximately four times greater than that of the relatively flat shoulder blade face (glenoid fossa).¹ The stability and movement of the shoulder is controlled by the rotator cuff muscles, ligaments, and the capsulolabral complex of the shoulder. The labrum is a fibrocartilaginous ring which attaches to the bony rim of the glenoid fossa.¹ The labrum doubles the depth of the glenoid fossa to help provide stability.² An analogy would be a parked car on a hillside with a chop block under the tire – the round tire being the humeral head, the road being the glenoid fossa and the chop block being the labrum.

The anatomy of the shoulder allows for great mobility yet sacrifices stability. For this reason the shoulder is one of the most commonly dislocated joints in the body. Shoulder dislocations can occur from trauma or from hyperlaxity (genetic or acquired looseness of the capsule and ligaments).

Traumatic anterior shoulder dislocations (in which the humeral head is displaced towards the front) most often occur when significant force is placed on the hand or lower part of the arm when the shoulder is abducted and externally rotated (Figure 2) or the arm is stretched straight out from the body, such as falling on an outstretched hand. When the shoulder dislocates anteriorly the capsule, ligaments and labrum are often torn. The anterior inferior part of the labrum (located between the 3 o'clock to 6 o'clock positions on the glenoid) is the area torn with this type of injury (Figure 3). In more severe cases when the labrum is torn a portion of the glenoid may be fractured, and this is referred to as a bony Bankart lesion.



Figure 2 Abducted—externally rotated position of the left shoulder

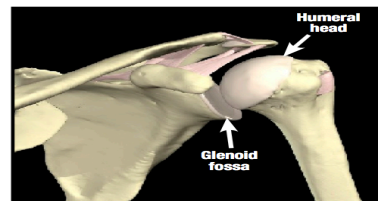


Figure 1 Anterior (looking from the front) bony anatomic shoulder model.

Image property of Primal Pictures, Ltd., primalpictures.com. Use of this image without authorization from Primal Pictures, Ltd. is prohibited.

Rehabilitation Protocol After Anterior Shoulder Reconstruction with Open Bankart Repair

Studies have shown that traumatic shoulder dislocations result in recurrent instability. The degree of recurrent instability is related to the patient's age and sport/activity level. Younger patients are more likely to have recurrent instability. Studies report recurrence rates from 65-95% for patients less than 20 years of age. Simonet³ reviewed 128 patients who suffered a shoulder dislocation and found that two years after the initial dislocation, 66% of patients who were less than 20 years old suffered a second dislocation while 40% of patients who were between 20 and 40 years old suffered a second dislocation. None of the patients older than 40 years old had suffered subsequent dislocations. Pevny studied 125 patients with shoulder dislocation over the age of 40 and found that while only 4% of these patients had recurrent instability, 35% of the patients had a rotator cuff tear. It is likely the injury pattern for dislocation changes as people age

Simonet also compared recurrent dislocations with athletes and non-athletes, with athletes having an 82% recurrence rate and non-athletes having a 30% recurrence rate. The athletic group also has different recurrent risk based on the type of sport, with overhead and contact sports being more likely to have recurrent dislocations.³

Restoring the normal anatomy of the shoulder is the most effective way of preventing recurrent instability and improving function in the young and athletic population. Restoring the anatomy primarily means repairing the torn labrum back to the rim of the glenoid. This is called a Bankart repair.

This can be done surgically with an arthroscopic technique or an open technique. The open technique involves a small incision in the front of the shoulder. The torn tissue is identified then suture anchors or bio-absorbable tacks are used to repair the torn tissue back to its anatomic location (Figure 4). The theoretic advantage of the open technique is that it allows for a more rigid fixation of the torn tissues.

Shoulder stability in healthy individuals is achieved through the structural integrity of the non-contractile (non-muscle) shoulder stabilizers (ligaments, capsule and labrum) and function of the rotator cuff and scapular muscles. Post-operative rehabilitation is essential after Bankart repair. The initial phase will focus on protection and progressive range of motion exercises to ensure proper healing of the repaired anatomical structures.

This will be followed by several phases focused on restoring and enhancing the strength and function of the rotator cuff and scapular muscles. In addition to improving the strength of these muscles it is important to improve the reaction time (neuromuscular control) to allow for appropriate protective stability during high speed movements or movements that place the shoulder at risk for dislocation as described previously. Return to sport decisions are determined by an individual's ability to demonstrate strength and control during these movements.

The rehabilitation guidelines below are presented in a criterion based progression. Specific time frames, restrictions and precautions are given to protect healing tissues and the surgical repair/reconstruction. General time frames are also given for reference to the average, but individual patients will progress at different rates depending on their age, associated injuries, pre-injury health status, rehab compliance and injury severity. The size and location of the labral tear may also affect the rate of post-operative progression.

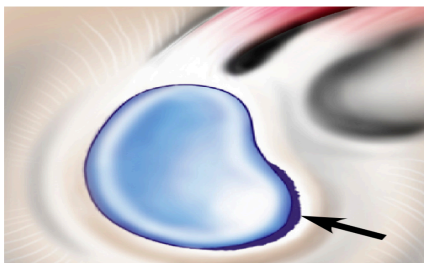


Figure 3 Bankart tear (anterior labral tear)
When looking at a right shoulder it would normally extend from 3 o'clock to 6 o'clock if imagining the glenoid as the face of a clock

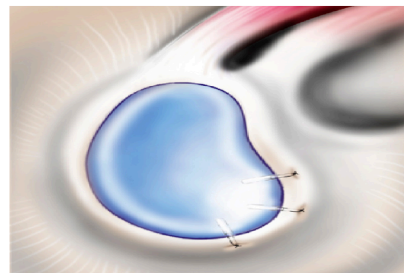


Figure 4 Fixation of the Bankart tear using three suture anchors in the bony glenoid and sutures approximating the labrum back to the bony glenoid

References

1. Wilk KE, Reinold MM, Dugas JR, Arrigo CA, Moser MW, Andrews JR. Current concepts in the recognition and treatment of superior labral (SLAP) lesions. *J Orthop Sports Phys Ther.* May 2005;35(5):273-291.
2. Perry J. Anatomy and biomechanics of the shoulder in throwing, swimming, gymnastics, and tennis. *Clin Sports Med.* Jul 1983;2(2):247-270.
3. Simonet WT, Cofield RH. Prognosis in anterior shoulder dislocation. *Am J Sports Med.* 1984 Jan-Feb;12(1):19-24.