

MADE FOR NEW YORK.



Dr. Laith M. Jazrawi

Chief, Division of Sports Medicine
Associate Professor Department of Orthopaedic Surgery

Rehabilitation Protocol After Posterior Shoulder Reconstruction with or without Labral Repair

The anatomic configuration of the shoulder joint (glenohumeral joint) is often compared to a golf ball on a tee. This is because the articular surface of the round humeral head is approximately four times greater than that of the relatively flat shoulder blade face (glenoid fossa).¹ The stability and movement of the shoulder is controlled by the rotator cuff muscles, ligaments, and the capsulolabral complex of the shoulder (Figure 1). The labrum is a fibrocartilagenous ring, which attaches to the bony rim of the glenoid fossa.¹ The labrum doubles the depth of the glenoid fossa to help provide stability. An analogy includes a parked car on a hillside with a chop block under the tire such that the round tire is the humeral head, the road is the glenoid fossa and the chop block is the labrum.

The anatomy of the shoulder allows for great mobility, yet this anatomical structure also sacrifices stability. The shoulder is one of the most commonly dislocated joints in the body. Shoulder dislocations can occur from trauma or from hyper-laxity (genetic or acquired looseness of the capsule and ligaments).

Traumatic posterior shoulder dislocations most often occur when significant force is placed through the arm when it is front of the body (Figure 2). When the shoulder dislocates posteriorly the capsule, ligaments and labrum often tear (Figure 3). Shoulder dislocations often lead to recurrent dislocation or subluxation, and posterior shoulder instability occurs when the humeral head subluxes or dislocates posteriorly on the glenoid. Sport activities that lead to posterior shoulder instability include heavy bench pressing and football linemen blocking—again with that mechanism of the arm straight out in front of the chest with force being applied through the arm to the shoulder.

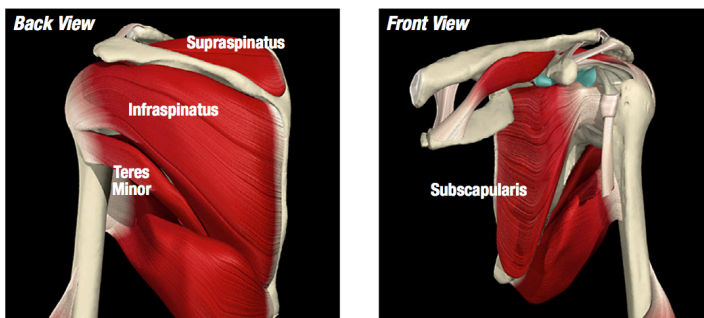


Figure 1 Rotator cuff anatomy

Image property of Primal Pictures, Ltd., primalpictures.com. Use of this image without authorization from Primal Pictures, Ltd. is prohibited.



Figure 2 Common mechanism of injury for posterior instability, arm straight out from chest with the body moving forward and a backward (posterior) force applied to the shoulder through the arm.

Rehabilitation Protocol After Posterior Shoulder Reconstruction with or without Labral Repair

For some athletes posterior instability can be treated non-operatively with rehabilitation. This often involves strengthening the rotator cuff and scapular muscles as well as improving the body's neuromuscular reaction to sudden changes of position or movement. Altering sport-specific techniques also is used in combination with rehabilitation. When these approaches are unsuccessful and posterior instability continues, the athlete may be left with the option of changing sports or having surgery. Surgical correction for posterior instability consists of capsulolabral repair and addressing the labral injury. This may mean debriding or removing frayed portions of the labrum or repairing tears with suture materials (Figure 4).

After surgery, rehabilitation plays a crucial role in maximizing the individual's functional outcome. In the early phases of rehabilitation after surgery it is necessary to protect the surgical repair to allow healing. This is done by allowing the patient to only move the shoulder in to certain ranges of motion and wear a sling most of the time that they are not doing rehabilitation exercises. The range of motion restrictions are outlined in Phase I. The rehabilitation guidelines are presented in a criterion based progression. General time frames are given for reference to the average, but individual patients will progress at different rates depending on their age, associated injuries, pre-injury health status, rehabilitation compliance and injury severity. Specific time frames, restrictions and precautions may also be given to protect healing tissues and the surgical repair/reconstruction.

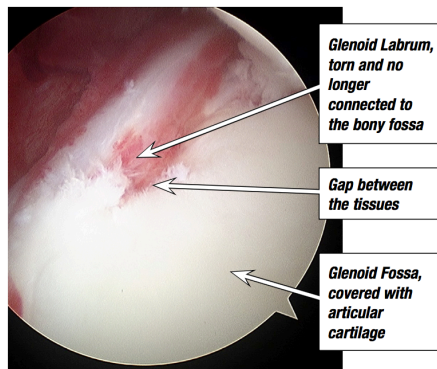


Figure 3 Posterior labral tear

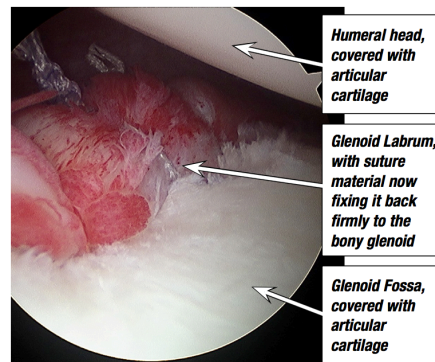


Figure 4 Posterior labral repair

Rehabilitation Protocol After Posterior Shoulder Reconstruction with or without Labral Repair

Phase I (Surgery to 6 weeks after surgery)

Precautions	<ul style="list-style-type: none"> ○ Sling immobilization at all times (in flexion, abduction and 0° of rotation) except for showering and rehab under guidance of PT
Range of Motion Exercises	<ul style="list-style-type: none"> ○ None for Weeks 0-3 ○ Weeks 3-6: Passive ROM – restrict motion to 90° of Forward Flexion, 90° of Abduction , and 45° of internal Rotation
Therapeutic Exercises	<ul style="list-style-type: none"> ○ Elbow/Wrist/Hand Range of Motion ○ Grip Strengthening ○ Starting Week 3: Begin passive ROM activities: Codman's, Anterior Capsule Mobilization
Other Suggestions	<ul style="list-style-type: none"> ○ Heat/Ice before and after PT sessions

Phase II (6 weeks to 12 weeks following surgery)

Precautions	<ul style="list-style-type: none"> ○ Sling immobilization for comfort only
Goals	<ul style="list-style-type: none"> ○ Begin AAROM/AROM ○ Goals: 135° of Forward Flexion, 120° of Abduction, Full External Rotation
Therapeutic Exercises	<ul style="list-style-type: none"> ○ Continue with Phase I exercises ○ Begin active-assisted exercises – Deltoid/Rotator Cuff Isometrics ○ Starting Week 8: Begin resistive exercises for Rotator Cuff/Scapular Stabilizers/Biceps and Triceps (keep all strengthening exercises below the horizontal plane during this phase – utilize exercise arcs that protect the posterior capsule from stress)
Other Suggestions	<ul style="list-style-type: none"> ○ Modalities per PT discretion

Rehabilitation Protocol After Posterior Shoulder Reconstruction with or without Labral Repair

Phase III (12 weeks to 16 weeks following surgery)

Range of Motion	o Progress to full AROM without discomfort
Therapeutic Exercises	o Advance Phase II exercises o Emphasize Glenohumeral stabilization, External Rotation and Latissimus eccentrics o Begin UE ergometer/ endurance ac
Other Suggestions	o Modalities per PT discretion

Phase IV (4 months to 6 months following surgery)

Range of Motion	o Full range of motion without discomfort
Therapeutic Exercises	o Continue with strengthening o Sport/Work specific rehabilitation – plyometric and throwing/racquet program o Continue with endurance activities o Return to sports at 6 months is approved
Other Suggestions	o Modalities per PT discretion

References

1. Wilk KE, Reinold MM, Dugas JR, Arrigo CA, Moser MW, Andrews JR. Current concepts in the recognition and treatment of superior labral (SLAP) lesions. *J Orthop Sports Phys Ther.* May 2005;35(5):273-291.